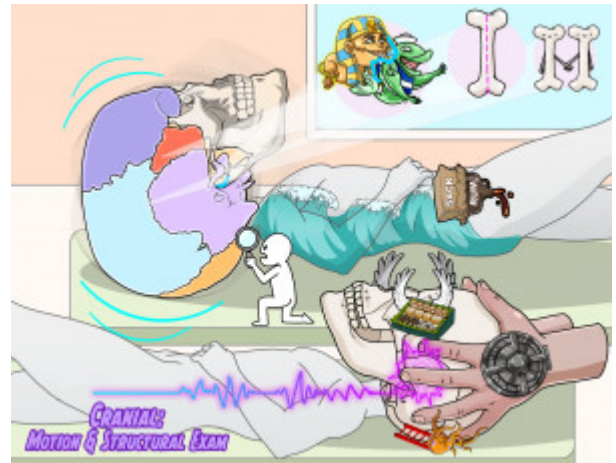


## Cranial: Motion and Structural Exam

Osteopathic cranial manipulative medicine (OCMM) is a system for diagnosing and treating somatic dysfunctions based on an understanding of cranial structure and function. OCMM is grounded in the work of William G. Sutherland, DO, who discovered the primary respiratory mechanism (PRM). Presented here is a review of the PRM and how osteopathic physicians assess motion of the cranial bones. The most important junction that is assessed is the sphenobasilar synchondrosis, which is composed of the midline bones, sphenoid and occiput. Paired bones of the cranium are also part of the PRM and can be assessed for motion. Through dural attachment, the sacrum moves as part of the PRM and can be assessed for nutation and counternutation. The main exam technique for assessing the PRM is the vault hold, in which the physician palpates the greater wings of the sphenoid, the lateral angles of the occiput, and the temporal bones. The physician then palpates the motion of the bones as well as the Cranial Rhythmic Impulse, the palpable sensation of the PRM cycling through inhalation and exhalation.



PLAY PICMONIC

### Physiology

#### Primary Respiratory Mechanism (PRM)

##### The Tide

The Primary Respiratory Mechanism (PRM) is a model for understanding the motion of cranial and intracranial structures. There are 5 phenomena observed in the PRM: (1) inherent motility of the brain and spinal cord, (2) fluctuation of cerebrospinal fluid, (3) mobility of intracranial and intraspinal membranes, (4) articular mobility of the cranial bones, and (5) mobility of the sacrum. The PRM describes a functional relationship formed by these phenomena. The PRM has two phases: inhalation and exhalation. Note that this is not the same as inhalation and exhalation of the lungs.

#### Sphenobasilar Synchondrosis (SBS)

##### The Junction between Sphinx and Bass-sailor

The SBS is the junction between the sphenoid and the occiput. Somatic dysfunctions of the SBS are important in the practice of OCMM. Normal motion of the SBS is described as flexion and extension. Flexion occurs when the angle of the SBS (formed by the inferior aspects of the sphenoid and occiput) decreases. Extension occurs when this angle increases.

#### Midline Bones

##### Midline Bone

The most important midline bones are sphenoid and occiput. Other examples include ethmoid and vomer. During the inhalation phase of the PRM, midline bones flex. During exhalation, they extend.

#### Paired Bones

##### Paired Bones

Paired bones include the temporal, frontal, and parietal bones, for example. During the inhalation phase of the PRM, paired bones externally rotate. During the exhalation phase of the PRM, they internally rotate.

#### Sacrum

##### Sack-rum

Motion of the sacrum is interdependent with motion of the SBS due to dural attachment at the level of S2. This motion occurs around a transverse axis near the S2 segment. During the inhalation phase of the PRM, the sacral base rotates posteriorly in a motion called counternutation. During the exhalation phase of the PRM, the sacral base rotates anteriorly in a motion called nutation.

## **Vault Hold**

### [Vault Hold](#)

The vault hold is a technique for examining the motion of the cranial bones. In the vault hold, the physician's hands encompass the cranial vault. The second digits contact the greater wings of the sphenoid, the third and fourth digits touch the temporal bones, and the fifth digits contact the lateral angles of the occiput. The first digits float above the parietals without touching the cranium. The vault hold is an excellent technique for finding SBS somatic dysfunctions, as the practitioner's hands have good contact with both the sphenoid and occiput.

## **Greater Wings of Sphenoid**

### [Greater Wings of Seafood](#)

The greater wings of the sphenoid reach laterally and help form the external surface of the cranial vault. Palpation of the greater wings allows the physician to assess sphenoid motion.

## **Lateral Angle of Occiput**

### [Ladder Angle of Octopus](#)

The lateral angle of the occiput is the part of the occiput that is just posterior to the occipitomastoid suture, a couple of inches behind the ear in adults. While much of the occiput is palpable on exam, this area is used in the vault hold to assess occiput motion.

## **Cranial Rhythmic Impulse**

### [Cranial Rhythmic Pulse](#)

Cranial Rhythmic Impulse (CRI) is the palpable experience of the PRM. CRI is most easily felt in the cranium, though it can be palpated in other parts of the body. The CRI is palpated as cycles of the PRM, both inhalation and exhalation. Around 10-14 cycles per minute is considered normal. Increased or decreased CRI can result from somatic dysfunction, trauma, or other medical or psychiatric conditions.