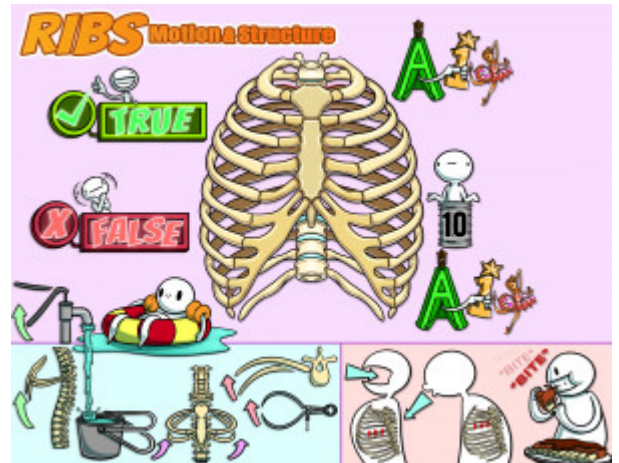


## Ribs: Motion and Structural Exam

A typical rib will have all of the following characteristics: a tubercle, a head, a neck, an angle and a shaft. An atypical rib is any rib who is missing one of these parts or one of these parts is dissimilar to the rest of the ribs at the corresponding section. Ribs 1-5 move in a pump handle motion, ribs 6-10 move in a bucket handle motion, and ribs 11 and 12 move in a caliper motion. A good test taking tip is that whenever you are trying to recall the movement of a rib during the test; imagine if a theoretical lung were expanding; what way would it push the rib in question. Of course lungs do not push ribs; lungs expand via negative pressure created by the diaphragm and ribs, but this is a helpful tool for test taking. There are two main somatic dysfunctions that affect the ribs. There are inhalation somatic dysfunctions in which the key rib to treat is the bottom rib. There are also exhalation somatic dysfunctions in which the key rib to treat is the top rib.



PLAY PICMONIC

### Anatomy

#### Typical (3-10)

##### Typical Ribs

A typical rib will have all of the following characteristics: a tubercle, a head, a neck, an angle and a shaft. The rib's tubercle articulates with the corresponding rib's transverse process. The head of the rib articulates with two vertebrae, the corresponding vertebrae and the vertebrae immediately superior. The neck is a narrowing between those two. The angle is the most posterior part of the rib and is where the bone changes direction. The shaft is the largest part of the rib and functions to protect the thorax.

#### Atypical (1, 2, 10, 11, 12)

##### A-tipi

An atypical rib is any rib that is missing one of the parts of a rib or if one of these parts is dissimilar to the rest of the ribs at corresponding spots. Any rib that articulates with only one vertebrae is also considered atypical. Rib 1 is considered atypical because it only articulates with T1. Rib 2 is considered atypical because it has a large tuberosity on the shaft. Rib 10 articulates with only T10. Ribs 11 and 12 articulate only with their corresponding vertebrae; they also lack tubercles.

#### Atypical Ribs Have "1"s and "2"s

##### A-tipi Ribs with (1) Wand and (2) Tutu

A good trick to remember which ribs are atypical is to know that any rib with the numbers 1 or 2 is atypical. Some anatomists do not consider rib 10 as atypical.

#### Rib 10

##### Rib (10) Tin

Rib 10 articulates with only T10. Some anatomists do not consider this rib atypical.

### True, False, and Floating Ribs

#### True (1-7)

##### True

Ribs 1-7 are considered true ribs because they attach to the sternum anteriorly via costal cartilage.

## False (8-10)

### False

Ribs 8-10 are called false ribs because they do not attach directly with the sternum. Each rib's costal cartilage attaches to the cartilage of the rib superior to it.

## Floating (11-12)

### Float

Ribs 11 and 12 are called floating ribs because they do not articulate with anything anteriorly.

## Rib Motion

### Pump Handle (1-5)

#### Pump Handle

Ribs 1-5 move in a pump handle motion. The anterior-most part of the rib that articulates with the sternum moves superiorly with inhalation and inferiorly with exhalation. The posterior-most part of ribs 1-5 stays relatively still compared with the most anterior portion. When seen from the sagittal view, the rib and the sternum together resemble a pump handle, and move like a spicket being pumped.

### Bucket Handle (6-10)

#### Bucket Handle

Ribs 6-10 move in a bucket handle motion. The anterior and posterior aspect of the rib remain relatively still during the respiratory cycle. The lateral most aspect of the shaft moves superiorly with inhalation and inferiorly with exhalation. This is called bucket handle motion because, from a sagittal view the shaft of the rib movement looks like the handle of a bucket being picked up and dropped repeatedly.

### Caliper (11-12)

#### Caliper

Ribs 11 and 12 move in a caliper motion. During inhalation they move laterally and inferiorly, and during exhalation they move medially and superiorly. This resembles the motion of a caliper.

## Key Ribs

### Bottom Inhalation

#### Bottom Inhalation

An inhalation dysfunction is any rib dysfunction in which the rib is "stuck" in inhalation and does not go fully into its range of motion during exhalation. In other words, the rib is stuck in the up position. Rib somatic dysfunctions are usually group dysfunctions. In an inhalation somatic dysfunction affecting multiple ribs, the rib that is the most important to treat is the rib that is most inferior. This is colloquially called the bottom rib.

### Top Exhalation

#### Top Exhalation

An exhalation dysfunction is any rib dysfunction in which the rib is "stuck" in exhalation and does not go fully into its range of motion during inhalation. In other words, the rib is stuck in the down position. Rib somatic dysfunctions are usually group dysfunctions. In an exhalation somatic dysfunction affecting multiple ribs, the rib that is the most important to treat is the rib that is most superior. This is colloquially called the top rib.

### BITE Mnemonic

#### Biting Ribs

For inhalation dysfunctions, the bottom rib is affected. For exhalation dysfunctions, the top rib is affected. Use the mnemonic "BITE" = bottom, inhalation; top, exhalation to recall these key ribs.