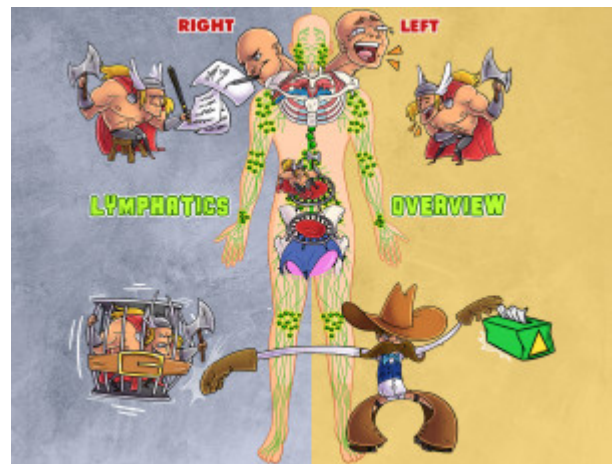


Lymphatics: Osteopathic Overview

The lymphatic system is a complex system of ducts and nodes that transport lymph from the peripheral tissues to the central venous system. Lymph returns to venous circulation via the subclavian veins. Two ducts empty into the subclavian veins - the right lymphatic duct empties into the right subclavian vein, while the left lymphatic duct (also known as the thoracic duct) empties into the left subclavian vein. The majority of the body's lymphatic return is routed through the thoracic duct. The right lymphatic duct is responsible for the right side of the body above the diaphragm (including right upper extremity, right head and neck, and right thorax), and the left lower lobe of the lungs. Lymphatic vessels cross multiple diaphragms in the body, where they may be restricted by fascial or muscular tension. These diaphragms include the thoracic inlet, the abdominal diaphragm, and the pelvic diaphragm. Somatic dysfunctions associated with dysfunctional lymphatic flow may be palpated as tissue texture changes, Chapman's points, tense diaphragms, or restricted thoracic cage motion.



PLAY PICMONIC

Left Lymphatic (Thoracic) Duct

Left Head and Neck

[Laughing-left Head and Neck](#)

The left side of the head and neck has a series of lymphatic vessels that drain into the left jugular lymphatic trunk, which drains into the left lymphatic (thoracic) duct, just before that vessel empties into the subclavian vein. From here, lymph will travel within the vein and empty into the superior vena cava. The left hemicranium includes the area of the left temporal, parietal, and occipital bones and is most often affected by sinusitis.

Left Thorax and Upper Extremity

[Laughing-left Thor-axe and Upper Extremity](#)

The left thorax includes the left upper lobe of the lungs and the left upper extremity. The left upper lobe drains into the left bronchomediastinal trunk, while the left upper extremity drains into the left subclavian trunk. These lymphatic trunks travel through the thoracic inlet and drain into the left lymphatic (thoracic) duct. They can be easily congested in the event of thoracic inlet somatic dysfunction.

Abdomen and Lower Extremities

[Abdomen & Lower Extremities](#)

The entire body below the diaphragm, including abdomen and lower extremities, is drained by a series of lymphatic vessels that empty into the thoracic duct at a convergence called the cisterna chyli, considered the inferior starting point of the thoracic duct. The thoracic duct continues cephalad along the anterior aspect of the thoracic spine and drains into the left subclavian vein. The thoracic duct is also known as the left lymphatic duct. Just like the right lymphatic duct, it receives tributaries from the left jugular, subclavian, and bronchomediastinal trunks before terminating in the subclavian vein. The thoracic duct is very susceptible to fascial distortion due to somatic dysfunctions of ribs, thoracic spine, and thoracic inlet.

Right Lymphatic Duct

Right Head and Neck

[Writing-right Head and Neck](#)

The right lymphatic duct drains the right head and neck via the right jugular trunk. This pathway can be easily congested with scalene tension, thoracic inlet restriction, and is often affected by sinusitis.

Right Thorax and Upper Extremity

Writing-right Thor-axe and Upper Extremity

The right thorax includes the entire right lung as well as the left lower lobe. These structures are drained by the right bronchomediastinal trunk, while the right upper extremity is drained by the right subclavian trunk. These trunks combine with the right jugular trunk to form the right lymphatic duct, which then empties into the right subclavian vein. Malignancies and infections of the thorax and extremities may manifest with enlarged lymph nodes in the axillary or supraclavicular chains.

Diaphragms

Thoracic Inlet

Lymph-line Drain

The thoracic inlet is the junction between the cervical spine and the thoracic spine, where the superior aspect of the rib cage begins. This anatomic plane contains Sibson's fascia, a transverse diaphragm often involved in somatic dysfunction of the thoracic inlet. Many structures, including lymphatic vessels, traverse the thoracic inlet and can be impinged by fascial tension. The thoracic inlet is often treated first when providing osteopathic manipulation directed at the lymphatic system, as the most proximal part of the lymphatic vessels need to have optimal flow before increasing flow upstream. This is sometimes called "unplugging the drain".

Thoracic Diaphragm

Thor-axe Diaphragm-trampoline

Also called the thoraco-abdominal diaphragm, this is the respiratory diaphragm. When this muscle becomes tense or distorted with organ dysfunction or somatic dysfunction, congestion can occur along the thoracic duct. The thoracic duct is the only lymphatic vessel that travels through the diaphragm, and congestion in the abdomen or lower extremities can be caused by congestion in this area.

Pelvic Diaphragm

Pelvic Diaphragm-trampoline

The pelvic diaphragm consists of the levator ani and coccygeus muscles. When these muscles become tense or compressed, the pelvic diaphragm can limit lymphatic flow from the lower extremities and lead to edema. This can be caused by physiological barriers such as injury or muscle spasm, or it could be caused by extrinsic pressure, like tight clothing when sitting.

Considerations

Tissue Changes

Tissue-box Delta-triangle

When assessing for lymphatic congestion, a sensation of fullness can often be felt along the diaphragms or other anatomical transition points, such as the thoracic inlet or outlet. It may be described as 'boggy' or 'warm' and is typically acute in nature.

Chapman's Points

Chaps-man

Chapman's points can be an excellent way to identify somatic dysfunction causing fascial distortion. This can be particularly helpful when diagnosing lymphatic conditions associated with visceral changes or distortion affecting a diaphragm.

Tense Pelvic Diaphragm

Tense-tent Pelvis Diaphragm-trampoline

The tense pelvic diaphragm can be felt during osteopathic evaluation. The tissues may feel full, boggy, and range of motion is frequently decreased. This finding can be associated with lower extremity edema.

Restricted Thoracic Cage Movement

[Restrictive-belt Thor-axe Cage Moving](#)

Restricted thoracic cage movement is consistent with a tense diaphragm or rib dysfunction. This can be palpated on osteopathic evaluation by monitoring rib cage movement through inhalation and exhalation, and is frequently associated with rib dysfunction.