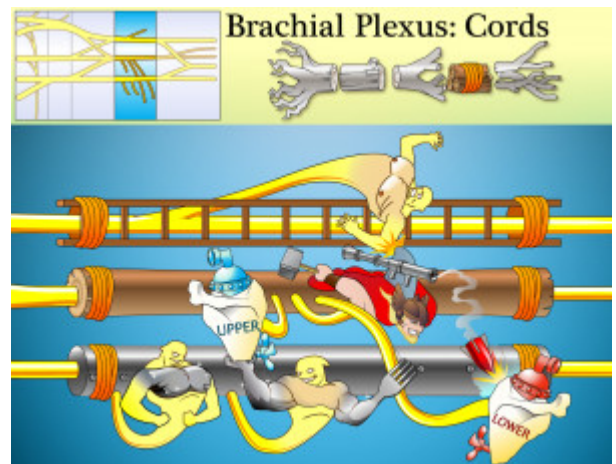


Brachial Plexus Cords

Lateral, posterior and medial cords are formed from the anterior and posterior divisions of the superior, medial and inferior trunks.



PLAY PICMONIC

Lateral Cord

Ladder Cord

Formed from the anterior divisions of the superior trunk (C5-C7). It branches in to the lateral pectoral nerve, musculocutaneous nerve, and the median nerve.

Lateral Pectoral Nerve

Ladder Pecks Nerve

Innervates the pectoralis major muscle.

Posterior Cord

Post Cord

Formed from the posterior divisions of all trunks (C5-T1). It branches into the axillary nerve (C5, C6) and radial nerve (C5, C6, C7, C8, T1). It also branches into the subscapular (C5, C6) nerves and thoracodorsal nerve.

Upper Subscapular Nerve

Upper Sub-scapula Nerve

Innervates the upper part of the subscapularis (internally rotates head of the humerus).

Thoracodorsal Nerve

Thor-rocket-dorsal-fin Nerve

Innervates the latissimus dorsi muscle, which medially rotates the arm.

Lower Subscapular Nerve

Lower Sub-scapula Nerve

Innervates the lower part of the subscapularis (internally rotates head of the humerus) and the teres major (medially rotates arm).

Medial Cord

Metal Cord

Formed from the anterior divisions of the inferior trunk (C8-T1). It branches into the median pectoral nerve, medial cutaneous nerve of the arm and forearm, and the ulnar nerve.

Medial Pectoral Nerve

[Metal Pecks Nerve](#)

Innervates the pectoralis major and pectoralis minor.

Medial Cutaneous Nerve of Arm and Forearm

[Metal Skin Nerve with Arm and Fork-arm](#)

Includes the medial brachial cutaneous nerve and the medial antebrachial cutaneous nerve which together innervate the medial aspects of the arm and forearm.