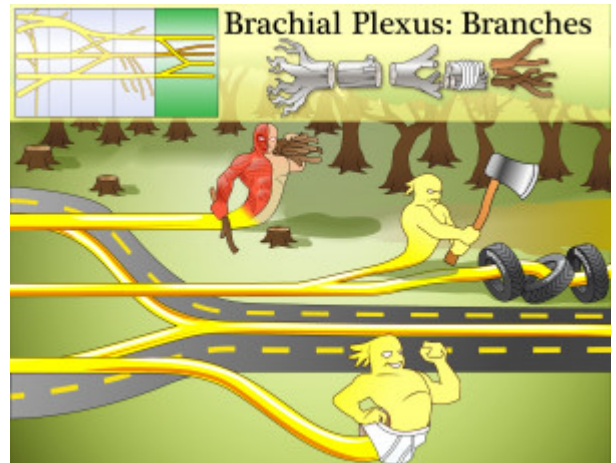


Brachial Plexus Branches

The Brachial Plexus Branches are the nerves that directly innervate muscles.



PLAY PICMONIC

Musculocutaneous Nerve

Muscle-and-skin Nerve

The musculocutaneous nerve innervates all flexors in the arm and the skin of the forearm.

Axillary Nerve

Ax Nerve

The axillary nerve innervates the deltoid and teres minor muscles, which laterally rotates the arm.

Radial Nerve

Radial-tire Nerve

The radial nerve innervates all extensors in the arm and forearm.

Median Nerve

Median-road Nerve

The median nerve innervates most flexors in the forearm and 5 hand muscles.

Ulnar Nerve

Underwear Nerve

The ulnar nerve innervates 1-1.5 flexors in the forearm and the remaining hand muscles.