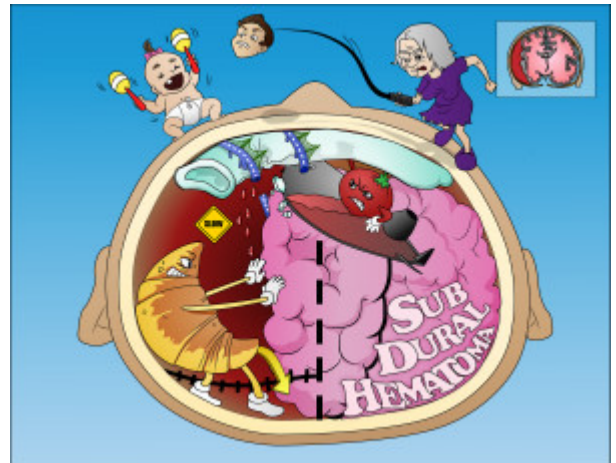


Subdural Hematoma

This is an acute or chronic condition due to venous bleeding that builds up between the dura mater and the arachnoid layer. It often occurs in acceleration-deceleration whiplash injuries and may present days to weeks after initial injury.



PLAY PICMONIC

Mechanism

Tear of Bridging Veins

[Tearing Bridge Vines](#)

This hematoma is a slow bleed and occurs due to a tear of bridging veins. Bridging veins travel through the subarachnoid space and subdural space. They can be injured leading to bleeding in the subdural space.

Slow Bleeding, Over Time

[Blood Dripping at Slow-sign](#)

The venous system is lower pressure than the arterial system and the bleeding is thus slow. Patients usually present within 48 hours of injury but may not present for days to weeks after injury.

Imaging

Subdural Space

[Sub-durex Space](#)

The subdural space exists between the dura mater and arachnoid layer. This is where blood accumulates in a subdural hematoma (below the dura).

Crescent-shaped on CT

[Croissant](#)

Subdural hematoma appears crescent-shaped on CT versus epidural hematoma, which is lens-shaped.

Crosses Suture Lines

[Crossing Sutures](#)

Unlike epidural hematoma, subdural bleeds can cross suture lines. This is a common finding on imaging.

Midline Shift

[Midline of brain Shifting](#)

As blood accumulates and pressure increases, subdural hematoma can lead to midline shift of the brain.

Causes

Elderly

Old lady

Due to brain atrophy and shrinking that occurs with aging, more tension is placed on the bridging veins. The brain can move more thus stretching the bridging veins and making them more susceptible to tear and injury.

Whiplash

Whip-head

Acceleration-deceleration injuries can lead to subdural hematoma. As the brain continues to move in the CSF after acceleration or deceleration, tearing of the bridging veins may occur.

Abusive Head Trauma (Shaken Baby Syndrome)

Shaking-maracas Baby

Babies have thin-walled bridging veins and are highly susceptible to subdural hematoma, particularly when they are shaken. Subdural hematoma in a baby is abuse until proven otherwise.