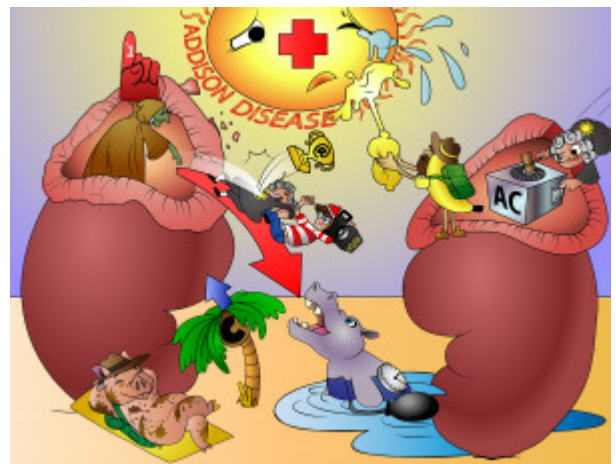


Addison's Disease

Addison disease is a chronic endocrine disorder yielding primary adrenal insufficiency. This is either due to adrenal atrophy or adrenal destruction from TB, metastases, autoimmune reaction, etc. Patients have decreased cortisol and aldosterone when examined. Manifestations of this disease include hyperpigmentation, hypotension, hyperkalemia and acidosis.



PLAY PICMONIC

Mechanism

Chronic 1° Adrenal Insufficiency

[Crone with #1 Foam-finger in damaged Adrenal-gland](#)

Addison disease is a chronic primary adrenal insufficiency which can be due to atrophy from exogenous cortisol intake, or due to destruction.

Atrophy

[@-trophy](#)

Atrophy of the adrenal glands can occur due to exogenous intake of high dose corticosteroids. After roughly a week of glucocorticoid intake, CRH and ACTH secretion decreases, and prolonged intake leads to physical atrophy of the adrenals. Beyond this point, it may take months to restore adrenal function, and patients may suffer from adrenal insufficiency.

Destruction

[Destroyed adrenal gland](#)

Destruction of the adrenal gland can be due to many etiologies. One common cause is autoimmune adrenalitis, while others include metastases of cancer from other organs, hemorrhage from Waterhouse-Friderichsen syndrome, amyloidosis or infection (TB, coccidiomycosis).

Symptoms

Deficiency In Cortisol And Aldosterone

[Down-arrow Court-of-Sol judge and Aldo-stereo](#)

Due to adrenal deficiency, hormones regularly produced are no longer secreted. Thus, patients have deficiencies in aldosterone and cortisol.

Skin Hyperpigmentation

[Hiker-pig with Hyperpigmentation](#)

A common manifestation of Addison disease is skin flexure and mucous membrane hyperpigmentation. John F. Kennedy's bronzed skin was attributed to being afflicted with Addison disease.

Increased POMC

Up-arrow Palm-tree-C

In Addison disease, there is a decrease of adrenal hormone secretion, but a large increase in ACTH. The precursor to ACTH is POMC (proopiomelanocortin), and is also a precursor to MSH (Melanocyte stimulating hormone). As the demand for ACTH increases, an increase in its precursor also leads to excess MSH production, leading to hyperpigmentation.

Hypotension

Hippo-BP

Decreased aldosterone leads to hypotension, or a decrease in blood pressure. Aldosterone works on Na⁺/K⁺ pumps to resorb Na⁺, which is followed by water, leading to increased blood volume, and subsequently, pressure.

Hyperkalemia

Hiker-banana

As aldosterone works on Na⁺/K⁺ pumps in the distal tubule and collecting ducts, it works to maintain homeostasis of K⁺, Na⁺, and fluids. In this disease, a lack of aldosterone means that excess K⁺ is not secreted into the tubular lumen. This can lead to hyperkalemia in patients.

Acidosis

Acidic-lemon

Metabolic acidosis occurs because Na⁺ resorption in the distal tubule is linked with H⁺ secretion under the influence of aldosterone. Low levels of aldosterone in the renal distal tubule leads to sodium wasting in the urine, and more importantly, excess H⁺ retention in the serum. This leads to acidosis.

Addisonian Crisis

Add-sun with Crying-crisis

Severe adrenal insufficiency leads to Addisonian crisis, which is a potentially life-threatening medical emergency which needs intervention. Patients can display coma, fever, convulsions, hypoglycemia, lethargy, and eventually death.

Diagnosis

ACTH (Cosyntropin) Stimulation Test

AC Stimulated

Diagnosis of Addison disease is supported with the ACTH stimulation test. A synthetic ACTH analog known as cosyntropin is administered either intramuscularly or intravenously. Serum cortisol levels are measured before and after this. If cortisol levels remain low after the injection, patients can be diagnosed with the disease.

Treatment

Exogenous Cortisol

Court-of-Sol judge coming in from outside

Treatment for this disease is to replace the missing cortisol to mimic normal physiologic levels.