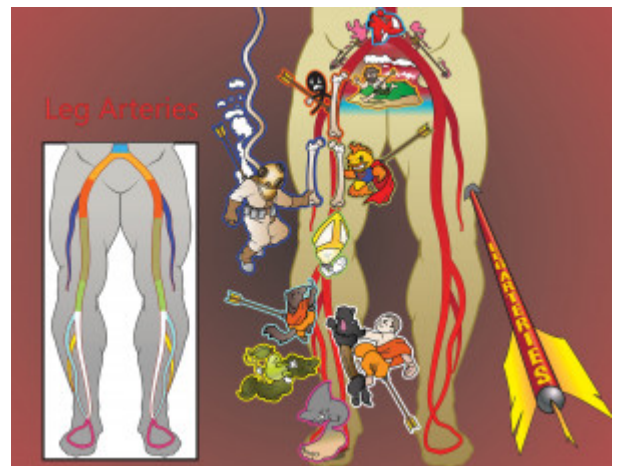


## Leg Arteries

The arterial tree is important for students to know, as this is a commonly tested anatomy subject. From the descending abdominal aorta, blood flow moves through the iliac artery and branches to the common femoral artery. This splits into the deep and superficial femoral arteries. The superficial branch turns into the popliteal artery, which first gives off the anterior tibial artery, and later splits into the posterior tibial and peroneal arteries. Lastly, these converge on the dorsalis pedis.



PLAY PICMONIC

### Descending Aorta

[Descending A-orca](#)

The descending aorta comes splits into the iliac arteries when it enters the hip. It comes from the thoracic and abdominal aortas.

### Iliac (Ilium)

[Island-bum](#)

The descending aorta gives off the common iliac arteries, which then split into the internal and external iliac arteries (the external gives off the femoral artery). For the sake of simplicity, this Picmonic combines the common and external iliac arteries (common turns into the external).

### Common Femoral

[Comma Femur](#)

Coming off as a continuation from the external iliac, the common femoral artery is another large thigh artery. This artery can be easily palpated and is often used to measure pulse in acute trauma situations and codes.

### Deep Femoral

[Deep-diver Femur](#)

The common femoral artery gives off the deep femoral artery (also known as the profunda femoral artery). This travels deeper than other branches of the femoral artery and does not leave the thigh.

### Superficial Femoral

[Super-fish Femur](#)

After the common femoral artery gives off the deep femoral artery, it continues on as the superficial femoral artery. It provides blood to arteries which circulate the knee and foot. It moves distally through the adductor canal and exits at the adductor hiatus to become the popliteal artery.

### Popliteal

[Pope-light](#)

The popliteal artery arises from, and is an extension of the superficial femoral artery. Once the superficial femoral artery emerges from the adductor hiatus, it is known as the popliteal artery. The termination of the popliteal artery is its bifurcation into the anterior tibial artery and posterior tibial artery.

### Anterior Tibial

[Anteater Tibetan](#)

The anterior tibial artery is a branch of the popliteal artery, and carries blood to the anterior compartment of the leg and dorsal surface of the foot.

## Posterior Tibial

### Post-terrier Tibetan

The posterior tibial artery carries blood to the posterior compartment of the leg and plantar surface of the foot, arising from the popliteal artery. The posterior tibial artery pulse can be readily palpated posterior and inferior to the medial malleolus and is clinically relevant because it is often examined by physicians when assessing a patient for peripheral vascular disease. It is very rarely absent in young and healthy individuals.

## Peroneal

### Pear-on-eel

The peroneal artery (also known as the fibular artery), supplies blood to the lateral compartment of the leg. It branches from the posterior tibial artery, just below the knee.

## Dorsalis Pedis

### Dorsal-fin Foot

The dorsalis pedis is an artery which is a continuation of the anterior tibial artery. It supplies blood to the dorsal surface of the foot. The dorsals pedis pulse can be palpated readily lateral to the extensor hallucis longus tendon on the dorsal surface of the foot, distal to the dorsal most prominence of the navicular bone. It is often examined, by physicians, when assessing whether a given patient has peripheral vascular disease.