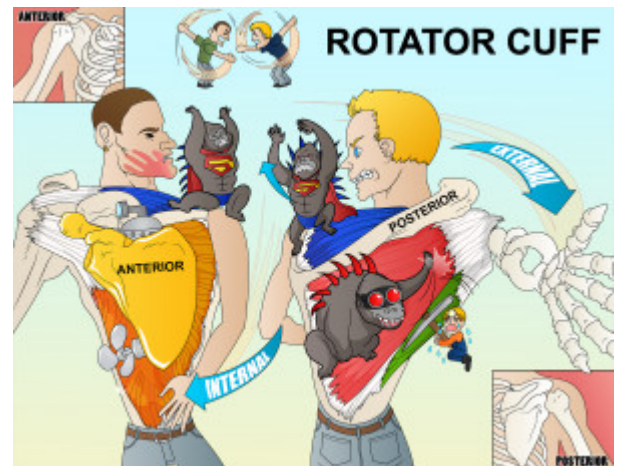


Rotator Cuff

The rotator cuff is a group of muscles and tendons which act to stabilize the shoulder. It is comprised of four muscles, the supraspinatus, infraspinatus, teres minor and subscapularis. External rotation is done with the teres minor and infraspinatus, while internal rotation is controlled by the subscapularis. Abduction of the arm occurs through flexion of the supraspinatus.



PLAY PICMONIC

External Rotation

[Rotating Externally away from body](#)

The rotator cuff is defined by the different actions of its muscles. External rotation of the arm is controlled by the infraspinatus and teres minor.

Teres Minor

[Teary Miner](#)

Teres Minor is a narrow, elongated muscle in the rotator cuff which serves to externally rotate the arm. It arises from the axillary border of the scapula and inserts on the greater tubercle of the humerus. The teres minor is seen in the posterior aspect of the scapula, below the infraspinatus. This muscle is innervated by branches of the axillary nerve.

Infraspinatus

[Infra-red-spine-ape](#)

The infraspinatus is a thick triangular muscle in the infraspinatus fossa. This muscle acts to externally rotate the arm. It originates in the infraspinatus fossa and inserts on the posterior facet of the greater tuberosity of the humerus. Innervation of this muscle comes from the suprascapular nerve.

Internal Rotation

[Rotating Inward across body](#)

Internal rotation of the humerus is another action of the rotator cuff. The subscapularis muscle carries out this function.

Subscapularis

[Sub-scapula](#)

The subscapularis is a large, triangle-shaped muscle that works to internally rotate the humeral head. When the arm is raised, it draws the humerus forward and downward. It is a powerful defense to the front of the shoulder joint, preventing displacement of the head of the humerus. It originates in the subscapular fossa and inserts in the humerus's humeral neck or lesser tuberosity. The subscapularis is innervated by the upper and lower subscapular nerves.

Abduction

[Abs-abducting](#)

The rotator cuff also functions to abduct the arm or raise the arm away from the midline. This is done with help from the supraspinatus.

Supraspinatus

Super-spine-ape

The supraspinatus is a small muscle of the upper back that originates from the supraspinatus fossa superior to the scapula and inserts in the greater tubercle of the humerus. It is innervated by the suprascapular nerve and functions to abduct the arm. This muscle helps with external rotation in conjunction with the infraspinatus and teres minor.