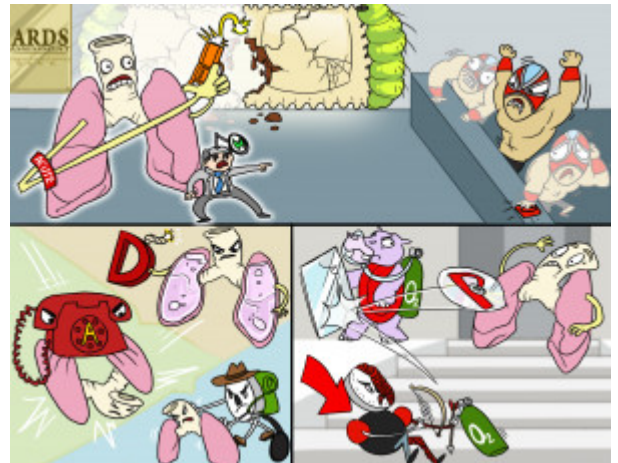


Acute Respiratory Distress Syndrome (ARDS) Assessment

ARDS is a sudden and progressive failure of the respiratory system in which the alveolar-capillary membrane becomes damaged. Damage to this membrane makes it more permeable to fluid, which can lead to difficulty breathing, atelectasis, and hypoxemia that is unresponsive to oxygen therapy. Patients who develop ARDS are typically afflicted by another illness or injury such as COPD, pneumonia, tuberculosis, aspiration, sepsis, shock, or fluid overload. Patients with this condition may also develop pulmonary hypertension, which is a late indicator of decreased lung compliance.



PLAY PICMONIC

Cause

Damaged Alveolar-Capillary Membrane

[Damaged Ravioli-Caterpillar Membrane](#)

Damage or injury to the alveolar-capillary membrane triggers the release of inflammatory mediators, eventually leading to increased membrane permeability. These changes in the lungs allow fluid from the interstitial space to enter and fill the alveoli. When this occurs, the alveoli can no longer function to oxygenate the blood that flows through the capillaries, causing impaired gas exchange.

Assessment

Restlessness

[Restlessness-wrestler](#)

Patients who are not getting enough oxygen will become restless, anxious, and diaphoretic. The body will attempt to compensate for the lack of oxygen by increasing heart rate, causing ARDS patients to become tachycardic.

Dyspnea

[Disc-P-lungs](#)

Changes in the lungs that interfere with gas exchange will cause patients with ARDS to become dyspneic. Difficulty breathing and the feeling of not getting enough air will lead to tachypnea, and eventually, respiratory alkalosis.

Refractory Hypoxemia

[Reflecting Hippo-blood-O2](#)

In patients with ARDS, the lungs are being adequately perfused, but gas exchange is disrupted due to atelectasis and fluid in the alveoli. The result is a V/Q mismatch and an intrapulmonary shunt, which lead to hypoxemia. Hypoxemia in this situation is refractory to oxygen therapy.

Decreased PaO2

[Down-arrow Partial Pressure-gauge Artery-archer with O2-tank](#)

Impaired gas exchange will cause a decrease in arterial oxygen levels in the blood, despite increasing oxygen concentrations used in oxygen therapy.

Diffuse Pulmonary Infiltrates

[D-fuse Lungs Filled-with-liquid](#)

Pulmonary infiltrates are abnormal areas of whiteness in the lung fields usually as a result of lung irregularities. An x-ray of healthy, air-filled lungs will appear black. However with ARDS, an x-ray of the patient's chest will reveal lungs that appear white, due to widespread infiltrates and minimal air spaces. These infiltrates often are composed of dense substances like blood, pus or cells, which may linger in the lung tissue of compromised patients. It is often referred to as whiteout or white lung.

Atelectasis

[A-telephone-collapsing-lungs](#)

Damage to alveolar cells causes decreased production of surfactant, the substance that functions to help keep alveoli open. This, in addition to accumulation of fluid in the alveoli, may contribute to lung collapse known as atelectasis.

Pulmonary Hypertension

[Lungs Hiker-BP](#)

The inflammatory process involved in ARDS will eventually cause destruction of the pulmonary vasculature and decreased lung compliance. As this occurs, pulmonary vascular resistance causes increased pressure in blood vessels from the heart to the lungs, known as pulmonary hypertension. Pulmonary hypertension is considered a late sign of decreased lung compliance.