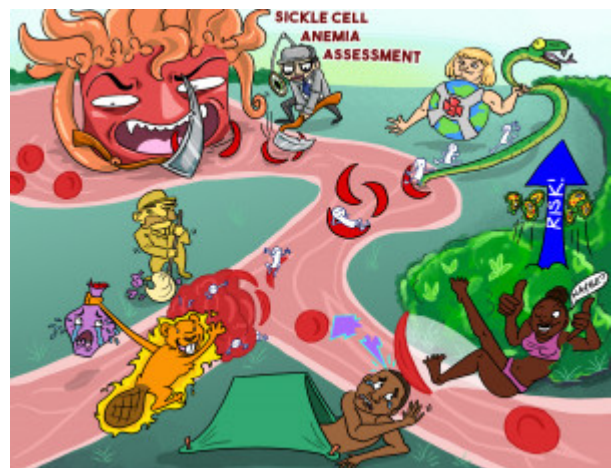


Sickle Cell Anemia Assessment

Sickle cell anemia (SCA) is an autosomal recessive genetic disorder that causes normal hemoglobin A to be partially or completely replaced by hemoglobin S. This disease is prominent among African Americans, although it can occur across all ethnicities. Unlike normal RBCs that are shaped like biconcave discs, RBCs are sickled or crescent-shaped in patients with SCA. In these patients, RBCs undergo rapid breakdown (hemolysis), which can lead to a build-up of bilirubin, causing noticeable yellowing of the skin and sclera. Patients may also experience severe pain in the hands, feet, joints, and abdomen. Other clinical manifestations include changes in vision, blood in the urine, and persistent, painful penile erections. Symptoms of thrombosis and infarction (pulmonary embolism and stroke) can occur during a vaso-occlusive crisis, in which blood vessels are obstructed by sickled RBCs causing tissue ischemia and pain. Keep in mind, that individuals with SCA are at an increased risk for infection due to splenic damage. If SCA is not diagnosed during infancy, patients with this disease may remain asymptomatic until a sickle cell crisis occurs.



PLAY PICMONIC

Cause/Mechanism

Hemoglobin S (Genetic Defect)

[He-Man-Globe and \(S\) Snake](#)

In patients with SCA, a genetic defect causes normal hemoglobin A to be partially or completely replaced by hemoglobin S, depending on the severity of the disease.

Sickle Shaped RBCs

[Sickle Shaped Red Blood Cell](#)

Unlike normal RBCs that are shaped like biconcave discs, RBCs are sickle or crescent-shaped in patients with SCA. Due to their abnormal shape, sickle-shaped RBCs tend to stick together, blocking blood flow within blood vessels throughout the body.

Assessment

Jaundice

[Jaundice-janitor](#)

Jaundice is common in patients with SCA due to the rapid breakdown (hemolysis) of abnormal red blood cells. Rapid hemolysis can lead to a build-up of bilirubin, causing noticeable discoloration of the skin and sclera.

Vaso Occlusive Crisis

[Vase Occluded in Crying-crisis](#)

Obstruction of blood vessels by sickled RBCs can block blood flow causing ischemia and pain. In patients who experience chronic vaso occlusive episodes, leg ulcers may develop. Symptoms of a vaso-occlusive crisis can include severe pain in the hands, feet, joints, and abdomen, stroke, changes in vision, yellowing of the skin and eyes, blood in the urine, and priapism (persistent painful erection).

Fever

[Fever-beaver](#)

Patients may present with a fever during a vaso-occlusive crisis.

Priapism

Pitching-a-tent

Sickled RBCs may prevent blood from leaving the penis during a vaso-occlusive crisis, causing priapism or a prolonged, painful erection.

Severe Pain

Severed Pain-bolt

Patients typically experience mild to excruciating pain during a vaso-occlusive crisis, due to tissue hypoxia. Pain commonly occurs in areas such as the abdomen, hands, and feet.

Considerations

Prominent in African Americans

African American

Sickle cell anemia is common among African Americans. Although it can occur in other ethnicities, the incidence among these populations is lower.

May be Asymptomatic

Thumbs-up with Maybe

If SCA is not diagnosed during infancy, patients with this disease may remain asymptomatic until they experience a crisis due to lack of adequate oxygenation, or dehydration.

Increased Risk of Infection

Up-arrow Risk Infectious-bacteria

Individuals with SCA are at an increased risk for infection due to splenic damage. Autoinfarction of the spleen typically occurs after the age of ten and renders the spleen unable to destroy bacteria and other foreign substances in the body.