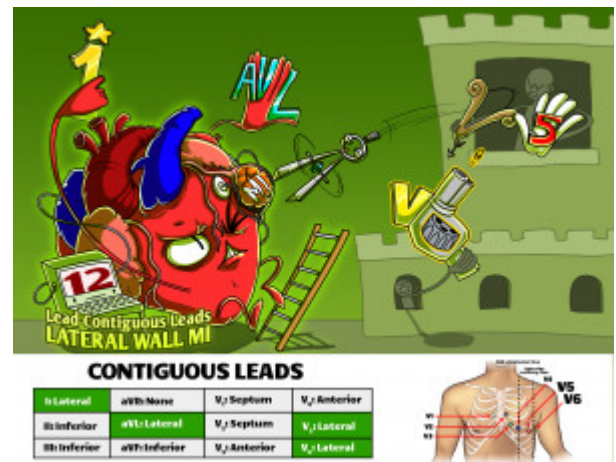


12 Lead Contiguous Leads - Lateral Wall MI

Lateral wall myocardial infarctions are characterized by acute ST-segment changes in leads I, aVL, V5 and V6. This ECG distribution is usually associated with an acute left circumflex artery lesion.



PLAY PICMONIC

Leads Elevated

Lead I

(1) Wand

Lead I is elevated in a lateral wall myocardial infarction.

Lead aVL

aV Left

Lateral wall myocardial infarctions are correlated with ST-segment changes in lead aVL.

Lead V5

V (5) Hand

Lead V5 shows ST-segment changes with a lateral wall myocardial infarction.

Lead V6

V (6) Shooter

ST-segment changes are observed in lead V6 with a lateral wall myocardial infarction.

Artery Affected

Circumflex

Circumference-compass

Lateral wall infarctions occur due to insult to the circumflex coronary artery, a branch of the left main coronary artery.