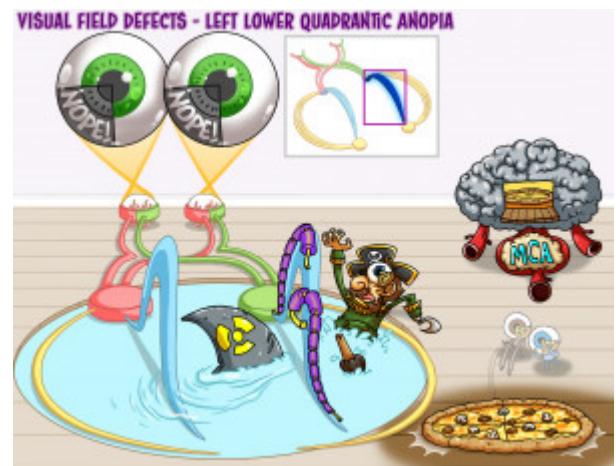


Visual Field Defects - Left Lower Quadrantic Anopia

Left lower quadrantic anopia is a loss of vision in the same fourth of each eye. The visual loss is in the inferior portion of the eye, giving a “pie on the floor” appearance. A lesion of the right dorsal optic radiation, part of the optic tract in the parietal lobe, leads to vision loss in the contralateral inferior fourths of each eye. An infarct of the middle cerebral artery which supplies the optic radiation leads to their ischemia and consequently the lower quadrantic anopia visual defect.



PLAY PICMONIC

Visual Field Abnormality

Left Lower Quadrantic Anopia

[Left Lower Quadrant Nope-eye](#)

This anopia consists of partial vision loss in both eyes.

Pie on the Floor

[pizza Pie on Floor](#)

A quarter of the same visual field is lost in the inferior portion of each eye, giving the appears of a slice of “pie on the floor.”

Location of Lesion

Dorsal Optic Radiation

[Radioactive Dorsal-fin](#)

This is the dorsal part of the pathway that carries information to the primary visual cortex on the shortest pathway via the internal capsule. Lesion of these fibers on the right side of the brain leads to loss of vision in the left lower quarters of both eyes.

Parietal Lobe

[Pirate](#)

The dorsal optic radiation is housed in the parietal lobe. Lesion of the optic radiation on one side of the brain leads to contralateral lower quadrantic anopia.

Causes

Middle Cerebral Artery (MCA) Infarct

[Metal Brain with Clogged middle artery](#)

Inferior branch of the middle cerebral artery supplies the optic radiations. An infarct of the MCA would cause ischemia in the areas which it supplies. A lack of blood supply to the right dorsal optic radiation would cause a lesion in this pathway, leading to left lower quadrantic anopia.