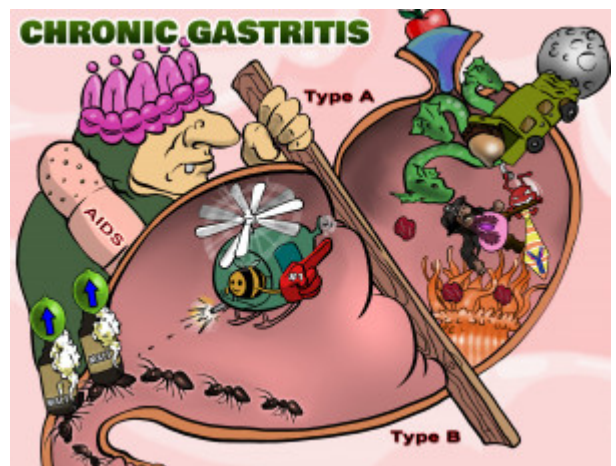


## Chronic Gastritis

Chronic gastritis is characterized by a progressive, irreversible atrophy of the gastric mucosa and glandular tissue within the stomach. Atrophy of the gastric mucosa leaves the stomach vulnerable to the corrosive and digestive properties of the hydrochloric acid within the stomach. There are two forms. Type A chronic gastritis, also called autoimmune atrophic gastritis, typically occurs in the fundus and body of the stomach. This type is characterized by an autoimmune response directed toward parietal cells in the stomach, which produce gastric intrinsic factor. Loss of these cells leads to pernicious anemia and achlorhydria. Type B chronic gastritis is more common and strongly associated with *Helicobacter pylori* in the antrum of the stomach. *Helicobacter pylori* is a gram negative bacteria that burrows below the stomach's mucus layer and produces urease, which breaks down urea in the stomach to ammonia. The ammonia helps neutralize gastric acid and create an alkaline environment which leaves the stomach susceptible to damage. Individuals with chronic type B gastritis are at increased risk for long term complications including MALT lymphoma. Risk factors for developing chronic gastritis include HIV and AIDs, as well as Crohn's disease.



PLAY PICMONIC

### Type A

#### Type A

##### (A) Apple

Type A chronic gastritis, also called autoimmune atrophic gastritis, typically occurs in the fundus and body of the stomach. This type is characterized by an autoimmune response directed toward parietal cells in the stomach, which produce intrinsic factor. Loss of these cells leads to achlorhydria and pernicious anemia.

#### Fundus and Body

##### Funnel

Type A chronic gastritis occurs in the fundus and body of the stomach as opposed to type B gastritis which occurs in the antrum. The fundus is the top most part of the stomach and marked off by a plane passing through the cardiac orifice horizontally.

#### Autoimmune

##### Auto-in-moon

Type A gastritis is characterized by the invasion of gastric tissue by self-reactive lymphocytes, leading to destruction of parietal cells. This also leads to the production of autoantibodies that attack both parietal cells and intrinsic factor. In addition, type A gastritis is associated with other autoimmune diseases such as type 1 diabetes.

#### Autoantibodies to Parietal Cells

##### Ant-tie-bodies at Pirate-cell

Parietal cells are stomach epithelial cells that secrete gastric acid and intrinsic factor in response to acetylcholine, histamine, and gastrin. Self-reactive lymphocytes cause destruction of these cells in autoimmune gastritis. This also leads to autoantibodies against parietal cells and intrinsic factor, causing decreased acid secretion and pernicious anemia.

#### Pernicious Anemia

##### Prune Anemone

Pernicious anemia is a megaloblastic anemia caused by the loss of gastric parietal cells, which secrete hydrochloric acid, and intrinsic factor. Intrinsic factor is necessary for the proper absorption of vitamin B12 in the ileum. Loss of vitamin B12 leads to megaloblastic anemia.

## Achlorhydria

### Acorn-hydra

Achlorhydria refers to absent production of gastric acid in the stomach. In type A gastritis, it is caused by destruction of parietal cells, which secrete gastric acid and intrinsic factor. Achlorhydria leads to impaired protein digestion due to inactivation of the enzyme pepsin, which is dependent on low gastric pH for activation. Decreased acid production also makes individuals more susceptible to bacterial overgrowth and infections.

## Type B

### Type B

#### (B) Bee

Type B chronic gastritis is more common and strongly associated with *Helicobacter pylori* in the antrum of the stomach. *Helicobacter pylori* is a gram negative bacteria that burrows below the stomach's mucus layer and produces urease, which breaks down urea in the stomach to ammonia. The ammonia helps neutralize gastric acid and create an alkaline environment which leaves the stomach susceptible to damage.

### Most Common Type

#### Foam-finger

Type B gastritis is the most common type of chronic gastritis.

### Helicobacter pylori

#### Helicopter

Type B chronic gastritis is more common and strongly associated with *Helicobacter pylori* in the antrum of the stomach. *Helicobacter pylori* is a gram negative bacteria that burrows below the stomach's mucus layer and produces urease, which breaks down urea in the stomach to ammonia. The ammonia helps neutralize gastric acid and create an alkaline environment which leaves the stomach susceptible to damage.

### Antrum

#### Ants

*H. pylori* typically infects the antrum of the stomach, which is the initial portion of the pyloric region of the stomach. Therefore, Type B chronic gastritis affects the antrum of the stomach.

### Increased Risk of MALT Lymphoma

#### Malt liquor Lymph-lime-foam

Mucosal-associated lymphoid tissue (MALT) lymphoma is a non-Hodgkin's lymphoma that can occur in the stomach, small bowel, salivary glands, thyroid and elsewhere in the body. It is associated with chronic immune responses to *H. pylori* and can be a complication of prolonged type B chronic gastritis.

## Associations

### HIV/AIDS

#### Band-AIDS

Individuals with HIV/AIDS are more susceptible to chronic gastritis.

### Crohn's Disease

#### Crown-of-intestines

Crohn's disease is a type of inflammatory bowel disease that can affect any part of the gastrointestinal tract and cause a wide variety of symptoms including bloody diarrhea, weight loss, skin rashes, and uveitis. Individuals with Crohn's disease are more susceptible to chronic gastritis.