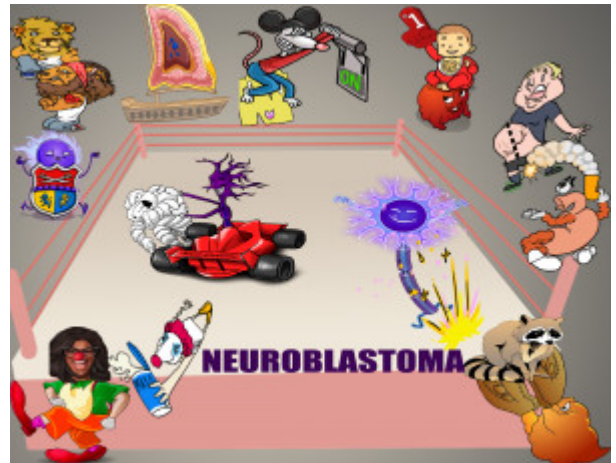


Neuroblastoma Characteristics and Presentation

Neuroblastoma is the most common malignancy in infancy with a median age of presentation of 18 months. It is a neuroendocrine tumor that originates from neural crest cells, in most cases due to somatic mutations leading to abnormal cell growth. It can present anywhere along the sympathetic chain but usually arises from the adrenal medulla. N-myc oncogene amplification is often seen in genetic analysis. Neuroblastoma has a diverse clinical presentation. Often, it presents as an abdominal mass that can cross the midline (vs Wilms tumor). Symptoms include gastrointestinal distress (from mass effect) and opsoclonus-myooclonus syndrome. In advanced cases, "raccoon eyes" or retroorbital metastasis, may be evident.



PLAY PICMONIC

Characteristics

Malignant Neuroendocrine Tumor

[Malignant-man Neuron-Indy-car](#)

The abnormal cellular proliferation of neural crest cells that give rise to neuroblastoma can occur anywhere along with the sympathetic nervous system. It is classified as a neuroendocrine tumor. The most common site are the adrenal glands (over half of the cases) followed by the abdominal paraspinal ganglia, thoracic paraspinal ganglia, and the neck.

Neural Crest Cells Origin

[Neuron with Crest](#)

Neuroblastoma originates from the abnormal proliferation of embryonic neural crest cells, which normally constitute the sympathetic ganglia and adrenal medulla. The abnormal proliferation of cells is due to different genetic mutations. Somatic mutations account for over 98% of cases. Although rare, some heritable gene mutations can lead to familial neuroblastoma.

Sympathetic Ganglia

[Symba-lion Gang](#)

Neuroblastoma can originate anywhere along the sympathetic nervous system including the adrenal glands and the sympathetic ganglia. The cells that give rise to the neuroblastic tumors originate from neural cell crests that are normally destined to form part of the adrenal medulla and sympathetic nervous system. Most tumors arise in the adrenal glands and in approximately 20% of the cases, it is found in the chest somewhere along the paravertebral sympathetic ganglia.

Adrenal Glands

[Adrenal Gland](#)

In over half of the cases, neuroblastoma originates in the adrenal glands. In children the most common cause of adrenal gland tumor is neuroblastoma. In contrast, pheochromocytoma is the most common adrenal gland tumor in adults.

Amplification of N-myc Oncogene

[N-Mickey-hat On-Switch](#)

Various genetic alterations have been identified in neuroblastoma. The most important one is the amplification of N-myc oncogene which is present in 20% of the cases. The gain-of-function of ALK oncogene has been identified in approximately 14% of cases. Both n-MYC and ALK alterations are associated with aggressive phenotype and poor prognosis. The variety of genetic alterations explain the wide spectrum of clinical presentation among patients. Testing for the amplification of n-MYC oncogene is important since it helps in establishing risk and treatment options.

Most Common Cancer In Infancy

#1 Foam-finger Infant with Tumor-guy

Neuroblastoma is the most common cancer in infancy and also the most common solid tumor outside of the cranium in children. The median age at the moment of diagnosis of neuroblastoma is 18 months. 40% of neuroblastomas are diagnosed by one year of age.

Clinical Presentation

Abdominal Mass That Can Cross Midline

Abdominal Mass Across Midline

In most cases, neuroblastoma arises from the adrenal glands and presents as a palpable abdominal mass that is firm and irregular and, in contrast to Wilms tumor, can cross the midline. Although a mass in the abdomen is the most common presenting location, other lesion sites include thoracic and cervical. Other associated symptoms are abdominal distension and pain, constipation, and hepatomegaly.

Gastrointestinal Distress

GI with Flare-gun

Neuroblastoma may present with abdominal distention and pain, constipation, nausea, vomiting, loss of appetite, and unexplained secretory diarrhea. Secretory diarrhea is one of the paraneoplastic syndromes and occurs when there is paraneoplastic production of vasoactive intestinal polypeptide (VIP).

Metastasis

Metastasis-mit

Most patients, over 50%, have distant metastases at the time of presentation. Neuroblastoma can metastasize by both lymphatic and hematogenous routes. Signs of metastasis include bone marrow suppression, proptosis, hepatomegaly, subcutaneous nodules, and opsoclonus/myoclonus. The most common sites of metastasis are bone marrow, liver, and skin.

Raccoon Eyes

Raccoon

Orbital findings such as periorbital ecchymosis, also known as raccoon eyes, which are due to metastatic spread to the retrobulbar region constitute a rare but classical finding of neuroblastoma. Another finding is heterochromia irides which correspond to different colors of the iris.

Opsoclonus-Myoclonus Syndrome

Oprah-clown and Mayo-clown

Opsoclonus-myoclonus syndrome (OMA) is a paraneoplastic syndrome that can be present in patients with neuroblastoma. It is characterized by rapid multidirectional eye movements and involuntary muscle spasms and is also known as "Dancing eyes, dancing feet". It is also associated with ataxia. The underlying mechanism is not known but may be due to an autoimmune reaction against the nervous system. Although less than 3% of children with neuroblastoma have OMA, children with OMA have in 50% of the cases underlying neuroblastoma.