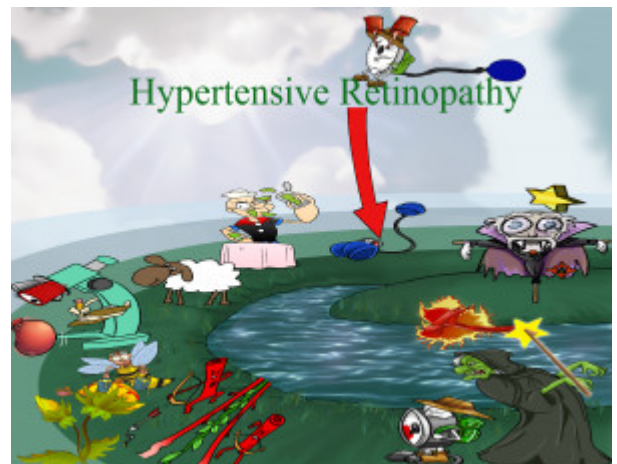


## Hypertensive Retinopathy

Hypertensive Retinopathy is a chronic microvascular complication of hypertension. Fundoscopic features include flame hemorrhages, arteriovenous nicking, retinal microaneurysms, cotton-wool spots, macular star, and papilledema. The treatment consists of lowering blood pressure.



PLAY PICMONIC

### Etiology

#### Chronic Hypertension

##### [Crone Hiker BP](#)

Hypertensive retinopathy is due to hypertension. Patients with this disease should be monitored for retinopathy during regular follow-up visits with a primary care provider.

### Fundoscopy Findings

#### Flame Hemorrhages

##### [Flame Hammer](#)

Flame hemorrhages with indistinct borders indicate that blood has accumulated in the retinal nerve fiber layer. A small rupture in a retinal blood vessel can result in this finding on funduscopy.

#### Arteriovenous Nicking

##### [Archer Vine Nectar](#)

Arteriovenous nicking occurs when atherosclerotic arteries compress their adjacent veins at nearly perpendicular angles. Bonnet sign is when the vein banks to one side distal to the arteriovenous crossing. Gunn sign is a tapering of the retinal vein on either side of the crossing while Salus sign is a deflection of the retinal vein as it crosses the arteriole.

#### Retinal Microaneurysms

##### [Red-tin Microscope-aneurysm](#)

Microaneurysms are saccular outpouchings of the capillary walls that can leak fluid and result in intraretinal edema and hemorrhage.

#### Cotton Wool Spots

##### [Cotton Ball Sheep](#)

Cotton wool spots (CWS) are localized, white-yellow, "fluffy" areas of nerve fiber layer edema. This causes interruption in axoplasmic flow resulting in damage to retinal ganglion cells.

## Macular Star

### [Macula Dracula with Star](#)

A macular star is a discrete, white-yellow lipid deposit in the posterior pole of the retina that occurs from increased vascular permeability.

## Papilledema

### [Popeye-edamame](#)

Papilledema is the swelling of the optic disc head. It presents with visual blurring and can be measured with the optic cup-to-disc ratio.

## Treatment

### Lower Blood Pressure

#### [Down-Arrow-BP-Cuff](#)

The treatment for hypertensive retinopathy is focused on treating the underlying condition - hypertension. Decreasing blood pressure will slow disease progression.