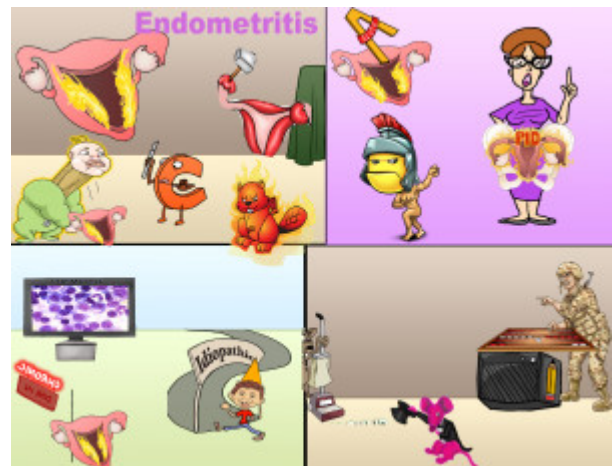


Endometritis

Endometritis, or inflammation of the endometrium, can be categorized into postpartum, acute, and chronic. Postpartum endometritis is associated with Cesarean births. It presents with fever and uterine tenderness. Acute endometritis is characterized by neutrophilic inflammation and is associated with pelvic inflammatory disease often in the context of sexually transmitted infections. Chronic endometritis is characterized by plasma cell infiltrate and is idiopathic. Outpatient management is usually with ceftriaxone and doxycycline but more severe cases may require gentamicin + clindamycin. In the case of clindamycin resistance, ampicillin-sulbactam can be administered.



PLAY PICMONIC

Postpartum

Postpartum Endometritis

Post-baby with Endometrium on Fire

Postpartum endometritis is often caused by retainment of lochia, which is ideal for bacterial growth. This can lead to postpartum endometritis and sepsis.

Cesarean Birth

C-section

Cesarean delivery is a risk factor for postpartum endometritis, increasing the incidence by 27% compared to vaginal birth. Other risk factors associated with postpartum endometritis include prolonged labor, retained products after conception/delivery/abortion, multiple cervical examinations, meconium in the amniotic fluid, and low socioeconomic status.

Fever

Fever-beaver

Clinical features associated with postpartum endometritis include fever, chills, and malaise. These infections are likely polymicrobial (e.g. Gardnerella, S. epidermidis). A fever associated with endometritis can also indicate the development of peritonitis or pelvic abscesses.

Uterine Tenderness

Tenderizer Uterus

Other clinical features associated with postpartum endometritis include uterine tenderness, lower abdominal pain, subinvolution (failure of the uterus to return to normal size following birth), and foul smelling lochia.

Acute

Acute Endometritis

Acute-angle with Endometrium on Fire

Acute endometritis involves non-obstetric inflammation of the endometrium and is usually related to pelvic inflammatory disease.

Neutrophils

[Nude-trojans](#)

Non-obstetric acute endometritis involves the presence of neutrophils within endometrial glands. Neutrophilic infiltrate is common after bacterial infection (e.g. Neisseria gonorrhoeae, Chlamydia spp.)

Pelvic Inflammatory Disease (PID)

[Ovaries-and-uterus on Fire](#)

Non-obstetric acute endometritis has a similar symptomatic presentation to postpartum endometritis. Additionally, as non-obstetric acute endometritis is unrelated to pregnancy, it is referred to as or considered a component of PID.

Chronic

Chronic Endometritis

[Crone with Endometrium on Fire](#)

Chronic endometritis is idiopathic though can be associated with infections, radiation therapy and/or intrauterine growths.

Plasma Cells

[Plasma Cell TV](#)

Non-obstetric chronic endometritis involves the presence of plasma cells along with lymphocytes within the endometrial stroma. Specifically, this includes the presence of five or more neutrophils in the superficial endometrium on the high-powered field (400x) and involvement of 1 or more plasma cells in the endometrial stroma on high-power field (120x).

Idiopathic

[Idiot-path](#)

Non-obstetric chronic endometritis is considered idiopathic. However, there are associations with retained products of conception, deliveries, and abortions. It is also associated with infections along with the presence of an intrauterine device (IUD).

Treatment

Gentamicin + Clindamycin

[Magenta-gentleman-mouse and Cleaning-mice](#)

The administration of IV gentamicin plus clindamycin every 8 hours is standard treatment for inpatients. Mild-moderate disease can be treated outpatient with ceftriaxone and doxycycline.

Ampicillin-Sulbactam

[Amp-pencil and Soldier-playing-backgammon](#)

In the event that there is resistance to clindamycin, an alternative treatment involves ampicillin-sulbactam (Unasyn) along with a 10-day course of PO doxycycline in chronic cases. The addition of metronidazole could also be considered if the patient recently had a gynecological procedure performed.