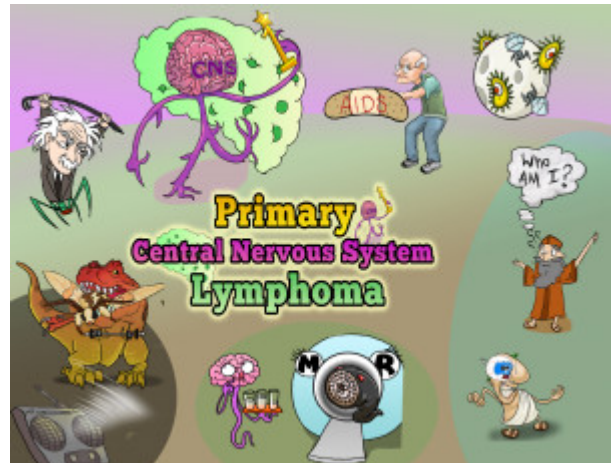


## Primary Central Nervous System Lymphoma



PLAY PICMONIC

### Associations

#### EBV (Epstein Barr Virus)

##### [Einstein-Bar Virus](#)

Primary Central Nervous System Lymphoma is an extranodal, high-grade non-Hodgkin B cell neoplasm that originates in the brain, spinal cord, eyes, and cerebrospinal fluid without evidence of systemic spread. The most common association of primary CNS lymphoma is EBV which is always positive in patients with HIV-related PCNSL. EBV is thought to cause malignancy due to the activation of cell growth factors and chronic stimulation of the immune system.

#### HIV/AIDS

##### [Band-AIDS](#)

Primary CNS lymphoma is one of the late complications of HIV infection. Other defining malignancies which can be seen in AIDS are Kaposi sarcoma, non-Hodgkin lymphoma (NHL) of high-grade pathologic type and of B cell or unknown immunologic phenotype, and invasive cervical carcinoma.

#### Elderly

##### [Old-man](#)

Primary CNS lymphoma has been seen to have an increased incidence in elderly patients.

#### Immunocompromised

##### [Moon-compromised](#)

Immunocompromised conditions such as HIV/AIDS patients are thought to increase the risk of having primary CNS lymphoma.

### Symptoms

#### Confusion

##### [Confucius](#)

Confusion or changes in mental alertness can occur in primary CNS lymphoma patients.

#### Memory Loss

##### ['Who am I' Thought Bubble](#)

Memory loss is one of the findings seen in primary CNS lymphoma patients.

## Seizures

### Caesar

Seizures can happen in patient with primary CNS lymphoma.

## Blurry Vision

### Blurry Eyes

Lymphomas that present within the eye can result in symptoms such as blurry vision, photophobia, pain, and floaters.

## Diagnosis

### MRI

#### M-R-eyes Machine

An MRI of the brain is recommended for these patients.

### Single, Ring-Enhancing Lesion

#### Single Ring Leech

A single, ring-enhancing lesion characterizes a lesion seen in primary CNS lymphoma. The presence of EBV and HIV/AIDS will support this diagnosis. This needs to be differentiated by toxoplasmosis which poses a similar risk except with multiple rings enhancing lesions on the imaging study.

### CSF Analysis

#### Brain-Spine-Fluid Sampler

CSF analysis should be obtained if leptomeningeal lymphoma is suspected, which includes flow cytometry, cytology, IgH (immunoglobulin heavy chain) and immunoglobulin light chain gene rearrangement, MYD88 mutational analysis and IL-10 if available.

## Treatment

### Methotrexate

#### Moth-T-Rex-ate

Methotrexate is proven to improve the survival of patients with primary CNS lymphoma.

### Radiotherapy

#### Radio Therapeutic-massage

Whole-brain radiotherapy (WBRT) has a high response rate (>90%) in treating primary CNS lymphoma. But this treatment is related to a high risk of relapse.