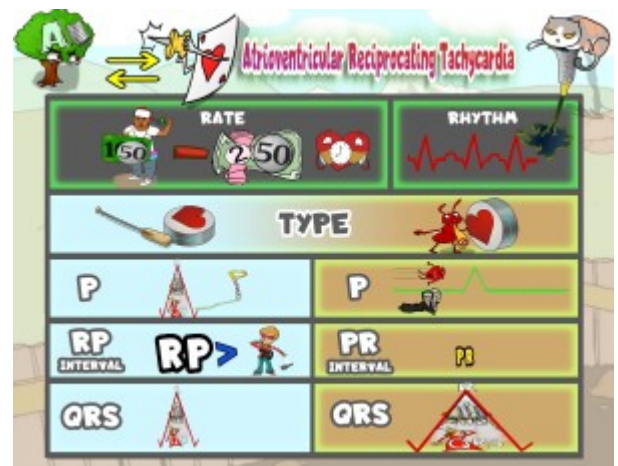


## Atrioventricular Reciprocating Tachycardia



PLAY PICMONIC

### Rate

**150-250 bpm**

[\(100\) Dollar-bill and \(50\) Cent - \(2\) Tutu \(100\) Dollar-bills \(50\) Cent Heart-timer](#)

AVRT is a fast heartbeat that needs an extra pathway to bypass the normal conduction system. It's a type of macroreentrant tachycardia that has two pathways, one regular via AV Node and one accessory that connects the atrium and ventricle. AVRT is the most common arrhythmia associated with Wolf-Parkinson-White syndrome, but other arrhythmias include AVNRT, atrial fibrillation with preexcitation, and atrial flutter. The heart rate can be around 150-250 bpm.

### Rhythm

**Regular**

[Regular Rhythm](#)

Atrioventricular reciprocating tachycardia rhythms are regular.

### Types

**Orthodromic**

[Oar-drum](#)

AVRT has two types, orthodromic and antidromic. The difference between the two types is the direction of the re-entry impulse through the atrioventricular node. Orthodromic circulates antegrade, and antidromic circulates retrograde.

**P Waves After QRS**

[P-pole-vault After Queen-Rocket-Ship](#)

In the lead II, III, and aVF, P can be seen retrograde after the QRS complex. If the retrograde P wave is present at the beginning of the ST segment, it can trigger ST segment depression.

**RP Interval >70 ms**

[RP Greater-than 70s-guy](#)

AVRT is seen with RP interval >70 ms. It can be longer because the accessory pathway becomes slower.

## Narrow QRS

### Narrow Queen's-Rocket-Ship

The QRS complex presents as narrow ( $<0.12$  Seconds) because the direction of the impulse is orthodromic, the direction from the atrium to the ventricle via the AV node.

## Antidromic

### Ant-tie-drum

Antidromic AVRT circulates retrograde, which differs from orthodromic AVRT, which circulates antegrade.

## No P Wave or P Wave Retrograde After QRS

### Nun-P-on-Waveform

P wave is most commonly not seen but, if present, can be seen retrograde after QRS. The RP intervals will be more than half the duration of the RR intervals.

## Shortened PR Interval

### Shortened PR

When an individual is not in tachyarrhythmia, the ECG may show a delta wave with a short PR interval due to early ventricular depolarization through the accessory pathway.

## Wide QRS

### Wide Queen's-Rocket-Ship

QRS complexes present as wide ( $>0.12$  Seconds) in antidromic AVRT because the impulse travels to the ventricles through the accessory pathway, causing the QRS complexes to be fully pre-excited.

## Management

### Catheter Ablation

#### Catheter-cat Baster

For individuals experiencing symptoms, as well as younger patients who are asymptomatic but meet certain criteria, radiofrequency ablation of the accessory pathway is the preferred treatment to prevent recurring arrhythmia. If symptomatic patients are not eligible for or choose not to undergo ablation, antiarrhythmic medication should be initiated. Flecainide, a Class 1C antiarrhythmic, is the preferred drug for preventing arrhythmia recurrence.