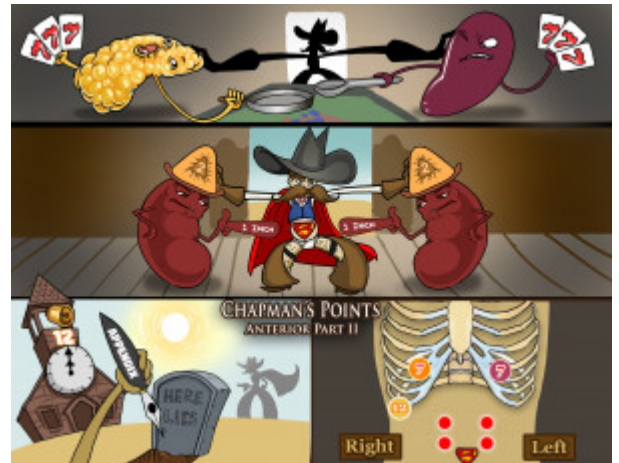


Chapman's Points - Anterior Part Two

Chapman's points or Chapman's reflex points are palpable areas of fascial tissue abnormality that develop secondarily to irritation or dysfunction of a target organ, and they are often considered to be a visceral reflex. They are characteristically small, smooth and firm areas that are 2-3mm in size. They are discretely palpable, and are described as tapioca-like or BB-like. Additionally, the palpable areas are partially fixed and often cannot be displaced. In this second of two Picmonics, the 7th intercostal space on the left is correlated to the spleen, while the 7th intercostal space on the right is correlated to the pancreas. In the supraumbilical area, one inch lateral and two inches superior, are the adrenal glands, while one inch lateral and only one inch superior to the umbilicus are the kidneys. Lastly, the 12th rib tip on the right is correlated with the appendix.



PLAY PICMONIC

Characteristics

7th Intercostal Space - Left

[Lucky \(7\) to the Left](#)

This space is the Chapman's reflex point believed to correspond with the spleen. It is found just inferior to the 7th rib on the left.

Spleen

[Spleen with spoon](#)

Firm rotary movement in the 7th intercostal space on the left side is thought to identify irritation or dysfunction in the spleen.

7th Intercostal Space - Right

[Lucky \(7\) to the Right](#)

This space is the Chapman's reflex point believed to correspond with the pancreas. It is found just inferior to the 7th rib, lateral to the costal cartilage on the right side.

Pancreas

[Pancreas with a pan](#)

According to Chapman, palpation of the 7th intercostal space on the right side corresponds with the pancreas and is believed to be able to identify irritation or dysfunction in the pancreas.

Supraumbilical

[Super-belly-button](#)

The supraumbilical region believed by Chapman to correspond with the adrenal glands and the kidneys while the umbilical area corresponds to the bladder.

Adrenal Glands

[Adrenal Hats](#)

Deep firm rotary movement in the periumbilical region 2 inches superior and 1 inch lateral to the umbilicus is thought to identify irritation or dysfunction in the adrenal glands.

Kidneys

[Kidneys](#)

Deep firm rotary movement in the periumbilical region 1" superior and 1" lateral to the umbilicus is thought to identify irritation or dysfunction in the kidneys.

12th Rib Tip - Right

[High Noon \(12\) to the Right](#)

This space is the Chapman's reflex point believed to correspond with the appendix.

Appendix

[Appendix-pen](#)

Gentle rotary movement around the 12th rib tip on the right is believed by Chapman to correspond with the appendix and thought to identify irritation of the appendix.