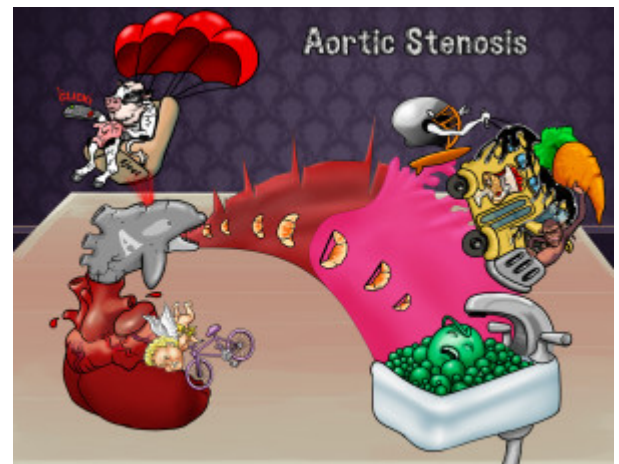


Aortic Stenosis

Aortic stenosis is a valvular heart disease characterized by the narrowing of the opening of the aortic valve. The aortic valve is a three-leafed valve that lies between the left ventricle and the aorta. This valve is normally open during systole, allowing blood to flow from the left ventricle to the aorta, and closes during diastole to prevent backflow of blood to the left ventricle. This heart valve can become stenotic due to age-related calcifications. A bicuspid aortic valve also predisposes to early calcifications of the valve. Stenosis of this valve causes a characteristic crescendo-decrescendo systolic heart murmur that typically follows a sharp ejection click, best heard at the second intercostal space to the right of the sternum. This ejection click is caused by the impact of the blood from the left ventricle against the partially fused aortic valve leaflets. The murmur characteristically radiates to the carotids and the apex. On a physical exam, the patient may also demonstrate pulsus parvus et tardus, which is a weak and late pulse on palpation relative to its usual character typically observed in the carotids. Symptoms of aortic stenosis typically depend on the degree of valve stenosis. Severe stenosis can lead to syncope and angina. Because the left ventricle must work harder to eject blood through the stenotic valve, it undergoes left ventricular hypertrophy. The stenotic valve can also mechanically damage red blood cells that pass through it, causing anemia and schistocytes, or helmet cells, to be found on a blood smear. There is an association between aortic stenosis and angiodysplasia of the large bowel, which is the second most common cause of hematochezia in the elderly (diverticuli being first).



PLAY PICMONIC

Characteristics

Age-related Calcifications

Old Calcified-cow

Aortic stenosis is most commonly caused by age-related calcification of a normal three-leafed aortic valve. These calcifications account for over 50% of cases of aortic stenosis.

Bicuspid Aortic Valve

Bike-cupid at A-orca Valve

Aortic stenosis can be caused by calcifications of a congenital bicuspid aortic valve which cause calcifications in a much younger population than the calcifications seen on a normal three-leafed valve. Bicuspid aortic valves account for 30-40% of cases of aortic stenosis.

Crescendo-decrescendo Murmur

Crescendo-crescents and D-crescents

Aortic stenosis is characterized by a crescendo-decrescendo murmur, which means the murmur intensity increases and then decreases during systole.

Systolic Murmur

Heart-squeeze

This valve is normally open during systole allowing blood to flow from the left ventricle to the aorta and closes during diastole to prevent backflow of blood to the left ventricle. Narrowing of the lumen and increased resistance to flow through the stenotic aortic valve causes a systolic heart murmur.

Ejection Murmur

[Ejection-seat](#)

An ejection murmur is defined as a systolic murmur that ends before the second heart sound produced by the ejection of blood from the heart into the aorta or pulmonary artery.

Ejection Click

[Ejecting with Clicker](#)

The crescendo-decrescendo systolic murmur typically follows a sharp ejection click best heard at the second intercostal space to the right of the sternum and radiates to the carotids and apex. This ejection click is caused by the impact of the blood from the left ventricle against the partially fused aortic valve leaflets.

Radiates to Carotids and Apex

[Radiator with Carrot and Ape](#)

This murmur classically radiates to the carotids and apex, which can help distinguish it from other heart murmurs.

Pulsus Parvus et Tardus

[Pulse Parfait Tar-bus](#)

On physical exam, the patient may demonstrate pulsus parvus et tardus, which is a weak and late pulse on palpation relative to its usual character typically observed in the carotids.

Syncope

[Sink-of-peas fainting](#)

Syncope is defined as a transient loss of consciousness and tone with rapid onset, short duration and spontaneous recovery. It is usually caused by global cerebral hypoperfusion. Syncope from aortic stenosis typically occurs during exertion and is an indication for aortic valve replacement.

Helmet Cells

[Helmet cell](#)

Helmet cells are fragmented red blood cells that can be caused by aortic stenosis due to mechanical damage of red blood cells as they pass through the calcified valves. Helmet cells are also known as schistocytes.